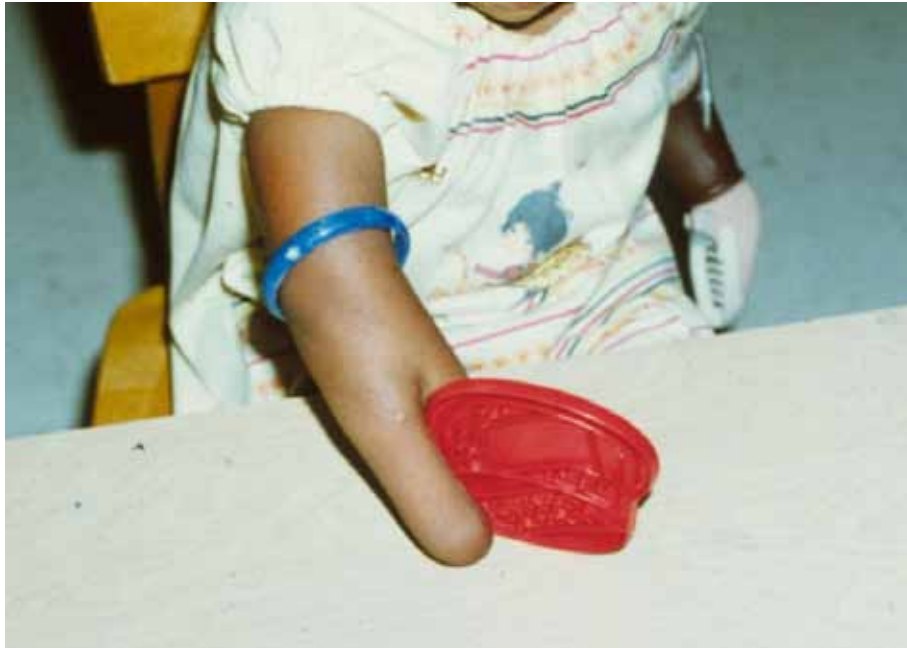

# Krukenberg's Operation In A Child



Introduction . . . . .	3
History . . . . .	3
Indications . . . . .	5
The Procedure . . . . .	6
Wound Closure . . . . .	7
Post Operative Care . . . . .	7
Long Run Follow-up . . . . .	8
Summary . . . . .	8

**John Lawrence M.D., Hugh G. Watts M.D.,  
& Joanna G. Patton OTR/L**



**GLOBAL HELP**  
HEALTH EDUCATION USING LOW-COST PUBLICATIONS

## Abstract

The purpose of the Krukenberg procedure in children is to provide sensate pinch to children who are neurologically intact and have a functional forearm and upper extremity, but are missing one or both hands. The operation is accomplished by splitting the forearm bones and creating two sensate pincers that can be used to grasp objects.

The advantages of the procedure are that it creates sensate pinch that allows skillful manipulation without the need to visually monitor it and it creates a durable extremity. The elements of a child's world such as water, sand and dirt will not affect its function. There is no need to constantly replace an outgrown prosthetic socket, nor is there need for continuing prosthetic repairs. The disadvantages are related to surgeons, parents, and peers who may have difficulty adjusting to the appearance of the arm.

In our opinion, this procedure is an appropriate choice of treatment for a child with a unilateral or bilateral amputation at the level of the wrist or the proximal metacarpals whether or not their vision is normal. We offer the operation to children who are developmentally over four years old because we believe that post-operative training would be more difficult at an earlier age.


## Authors

### John F. Lawrence, MD



John F. Lawrence is an experienced pediatric hand surgeon. He has been active in teaching children's reconstructive hand surgery at Shriners Hospital Los Angeles for over 20 years. He was born in Rochester, N.Y., educated at Pomona College, University of Rochester, and UCLA. He is a member of the American Society for Surgery of the Hand. He is an advocate of global medical education and has actively participated in Children's orthopedic care in South America.

### Hugh G. Watts, MD



Dr. Watts is a pediatric orthopedic surgeon with a keen interest in health problems from a global perspective. Born in Japan, educated in Canada and the U.S.A., he worked for two years in Afghanistan, and five years in Saudi Arabia. He has lectured extensively in the U.S.A., Europe, the Middle East, and Central and South America.

### Joanna G. Patton, OTR/L



Joanna G. Patton is a registered occupational therapist who has extensive experience treating children with limb deficiencies or amputations. She has been a clinical therapist and instructor at the Child Amputee Prosthetics Project at both UCLA and Shriners Hospital for Children in Los Angeles. Publications include chapters in prosthetic textbooks which discuss occupational therapy treatment for children with various types of limb loss.

### Deborah C., Graphics Associate



Deborah works as a Graphics Associate for Global HELP and assisted in the formatting of this publication.



## GLOBAL HELP

The Global HELP organization provides free health-care information to developing countries and helping to make medical knowledge accessible worldwide. See [www.global-help.org](http://www.global-help.org) or [www.orthobooks.org](http://www.orthobooks.org)

## Introduction

The Krukenberg procedure is an operation designed to provide grasp in patients who don't have a functioning hand. A major advantage of the procedure is that the patient in addition to being able to grasp objects without using a prosthesis, has the ability to feel objects that are being grasped. This procedure can be done in children who are missing their hand(s) as a result of either a congenital absence or trauma.

In essence the surgery separates the forearm bones similar to doing a release of syndactyly of the fingers. The separation is extended to the level of the pronator teres and covers the separated bones with the available sensate forearm skin.

This procedure provides excellent pinch and small grasp in children with absence of one or both hands.

Children with absent hands, especially those due to congenital deletions, commonly prefer not to wear upper extremity prostheses. Krukenberg's operation provides a procedure that adds function without the encumbrance of added prosthetic weight and the uncomfortable heat from wearing the socket.

An additional advantage is that a child may do functions where the arm will get wet, which would otherwise damage a prosthesis.

## Regions of the world where prosthetic facilities are limited

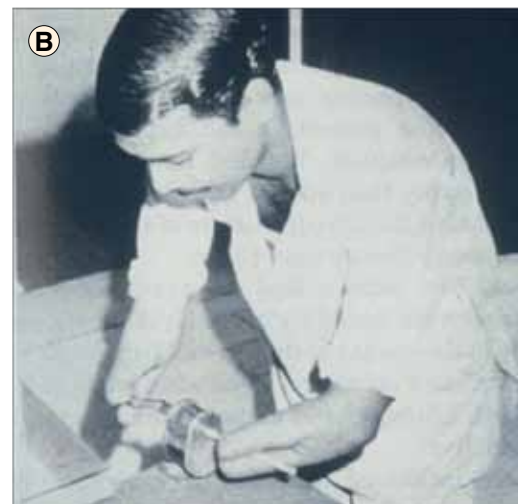
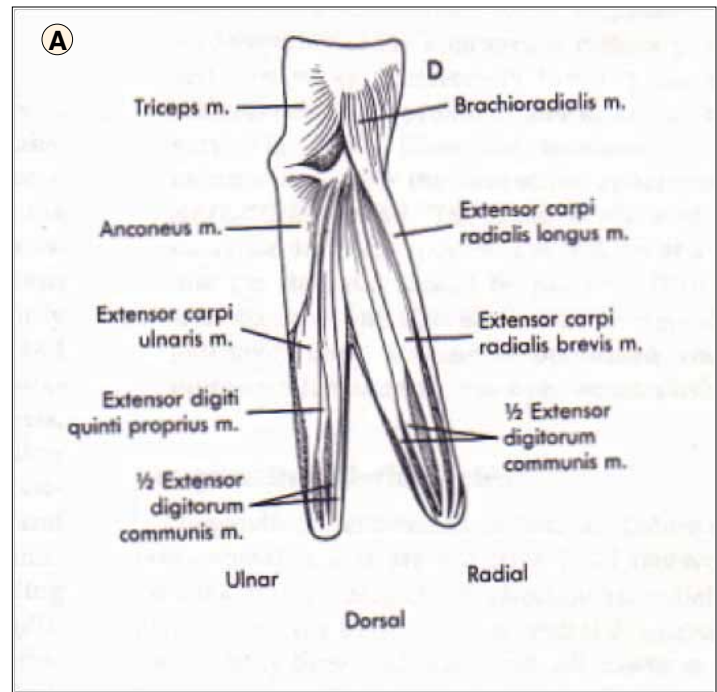
This operation is particularly useful in regions of the world where prosthetic facilities are limited, or where the cost of a prosthesis and its repair are unreasonably expensive. Dr. Ronald Garst, an American missionary surgeon who worked for many years in Bangladesh was very enthusiastic about the benefits of Krukenberg's operation. Here one of his patients who had lost both his hands is shown sharpening a pencil while working in the hospital record room:

The country of Bangladesh honored this work by publishing a postage stamp during the International Year of Disabled Persons in 1981.

The purpose of this monograph is to provide enough information so that this useful and very gratifying procedure can be made available for general use in appropriate children.

## History

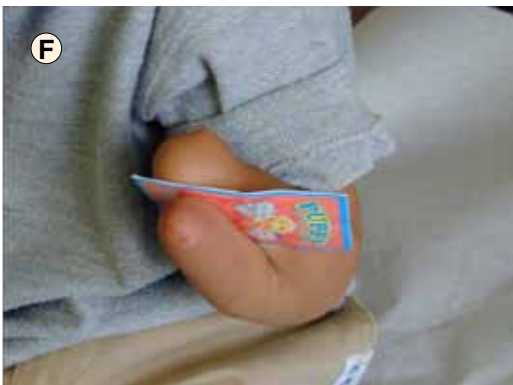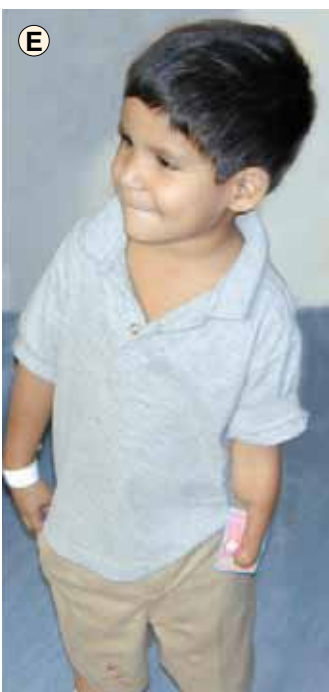In 1917 Hermann Krukenberg first reported on the conversion of a forearm stump into pincers by separating the radius and ulna in a bilateral adult amputee. [#1] The initial utilization of this procedure was primarily in amputees from World War One. The first description of the use of this procedure in children in the English medical literature was in 1933. Colp and Ransohoff described use of the Krukenberg in two pediatric patients. Both were teenagers with unilateral losses- one the result of a congenital amputation and the other from trauma. [#2] Albert Swanson and Genevieve DeGroot Swanson in 1964 [#3] described the unilateral use of the Krukenberg procedure in the juvenile Amputee. They presented four patients each with bilateral absences in whom one side was fitted with a standard prosthesis and on the other the Krukenberg was performed. The operated side became the major hand in each







Drs. Genevieve & Albert Swanson in 2008



and none desired to wear a prosthesis on the operated side. They later presented long term follow-ups on several patients [#4] (One of these patients has since written a book about his experiences. [#5])

### Cosmetic Appearance vs. Function

Modifying the forearm in this fashion has not been well accepted in the United States. Statements from some reliable sources are the following:

James Burkhalter et al: "Initially the Krukenberg procedure was indicated for blind below-elbow amputees. I think there is little enthusiasm for the Krukenberg amputation in this country (i.e. the USA) and that is because of our lack of experience and understanding of the procedure and what really can be done functionally." #6

Harrison and Mayou 1977: "Krukenberg's ingenious operation, first described in 1917, for whole hand amputees has a limited acceptance outside Germany and Scandinavia" #7.

Swanson 1964: "The lack of interest and almost universal antipathy toward this procedure should be overcome, it is a useful procedure which should be available to more of these unfortunate patients." #3

In the U.S.A. the trend has been to restrict the operation to those who have bilateral amputations and are also blind. In such a situation the retention of sensation is critical. This debate is characterized by the intensity of emotion generated on both sides.

While medical personnel in the USA have had such a dread of the cosmetic outcome of a Krukenberg procedure, this opinion is not as strongly shared by those in the non-medical community. Schwartz, Watts & Patton [#8], surveyed a non-medical population (n= 226) in Los Angeles of people ranging from age 8 to 82 years. They were questioned after viewing a video of a 5 year old child, who had had a Krukenberg procedure, performing various tasks with the Krukenberg compared to the same child doing the same tasks with an upper extremity prosthesis fitted over the Krukenberg arm. The age of the respondent was a determining factor in that teen-agers and older adults (grandparent age) found the Krukenberg less appealing, although they felt that function was better. Young children and young adults (parent age) did not find the procedure cosmetically a disadvantage and agreed that function was better. The majority of respondents said that they would prefer to see a child in public at a restaurant using the Krukenberg versus a prosthesis. Genevieve Swanson's concept of "active versus passive cosmesis" may provide the reason. Passive Cosmesis refers to appearance at rest whereas Active Cosmesis refers to the appearance with motion. An example is a paralyzed hand— at rest, it appears quite normal. However, with attempts at use, it is obvious that it does not function normally and is not as cosmetically acceptable. The Krukenberg is similar in that the extraordinary dexterity it allows makes it seem more natural because of its usefulness to the patient. Ultimately approximately half of those questioned would choose

a Krukenberg for themselves if they had an appropriate upper extremity amputation. Schwartz et al concluded that “While medical personnel in the USA have had such a dread of the cosmetic outcome of a Krukenberg procedure, this opinion is not strongly shared by those in the community. Since the functional advantages of the operation are great, the Krukenberg should be considered as an option for any child missing a hand”. It gives the patient an autonomous, functional upper extremity with sensory feedback.

It should be further noted that the presence of a Krukenberg procedure does not prohibit the use of a prosthesis worn over top of the Krukenberg-modified residual limb if the patient desires to do so. Several of our patients have had a prosthesis made, but few have chosen to wear them.

A recent multi-center study has shown that children with unilateral transradial limb deficiencies often do not wear their prostheses. From a clinical point of view children with short or mid-below elbow deficiencies may wear a prosthesis (full or part time) for a specific developmental time period or for certain activities. Children with transcarpal or transradial wrist level deficiencies are not usually appropriate candidates for prosthetic fitting because they already have excellent length and function except for the ability to grasp. Therefore the decision practically becomes whether to do the Krukenberg or do nothing.

## Indications and Contraindications

### Vision

For blind children, the retention of sensation that the operation provides makes the choice of the Krukenberg procedure especially desirable. However, we believe that the indications should include children with normal eyesight who have either bilateral or unilateral absence of the hand because of the greater functional use it creates.

### The length of the forearm

The desirable length of the residual forearm depends in part on the age of the child. In children under about five or six years of age, the length of the stump should be at about the transcarpal, or wrist level. As the children get older and bigger, arm deletions at the mid-forearm level or longer can be chosen. The goal is to end up at maturity with a pincer length of 10 cm or greater.

### Age

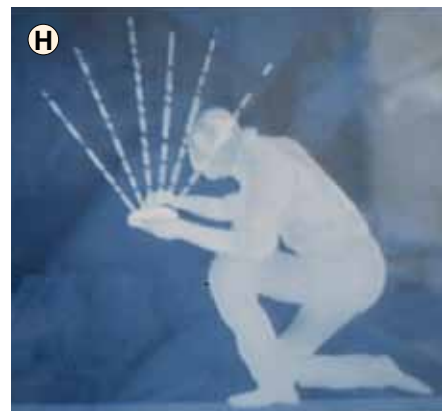
We offer the operation to children who are developmentally over four years old because we believe that post-operative training would be more difficult at an earlier age. We feel that the child must have sufficient advancement of their psychosocial development to understand and cooperate with the post-operative exercise program.

### Children who are victims of Explosive Remnants of War

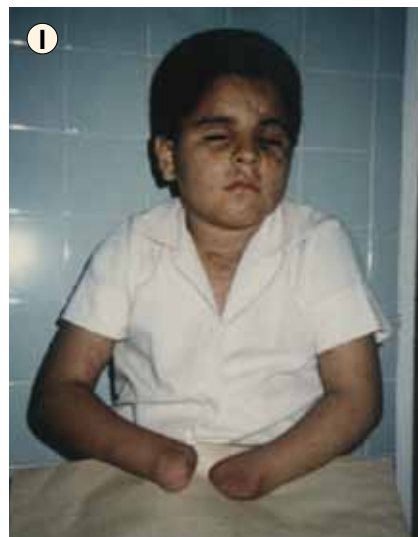Children are particularly vulnerable to explosive remnants of war (ERW) in a number of ways [9]. The natural curiosity of children puts them at great risk for landmine injuries because they will pick up the objects thinking that they are toys (see photo of Butterfly mines). The blast from ERWs that are picked



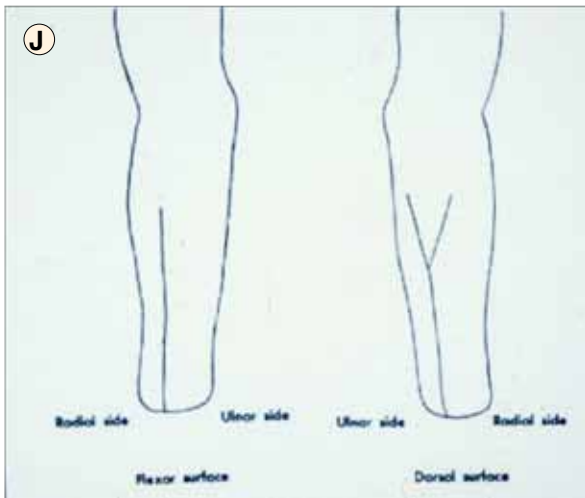
*Butterfly land mine that can be dropped from helicopters by the thousands are readily mistaken by children to be toys.*



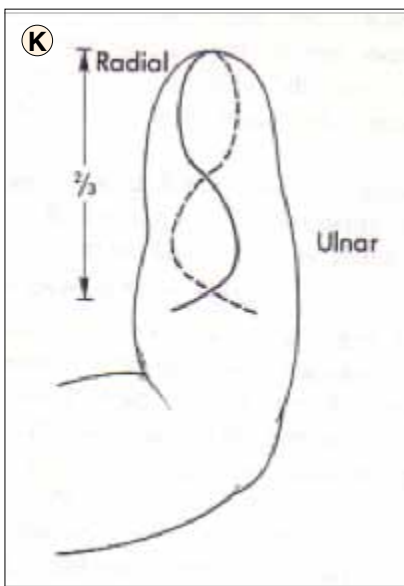
*Effect of an explosive devise picked up in the hands*



*This boy from Colombia, South America picked up from the ground a land mine that he thought was a toy. He lost both arms and was blinded in both eyes.*



The skin incision is placed so that at the end of the operation, the skin that lies between the two digits has sensation and the operative scars are not in the pinching area.



An alternative choice for the skin incisions

up in the hands frequently leads to loss of both hands as well as severe facial and head injuries, commonly including blindness and deafness. The phrase “Explosive Remnants of War” (ERW) is becoming the generic term to refer to land mines, unexploded ordnance, improvised explosive devices and cluster bombs.

The UN estimates that currently children in at least 80 countries are threatened by the contamination by ERW on the land on which they live [#10] For every land mine cleared, approximately 20 more are laid. While the cost of manufacturing many of these explosives is estimated to be about \$3 to \$27 [#11] the cost to clear each mine is estimated at \$300 to over \$1000. Land mines last for many decades, especially in very dry countries such as Libya where World War II mines still cause injuries. In the years since the end of the war in Vietnam, over 40,000 Vietnamese have been killed or injured by landmines and unexploded ordnance left behind from that conflict [#12]

What prosthetic apparatus should be prescribed for a child who has sustained a bilateral upper extremity forearm amputation as a result of an injury sustained while picking up an explosive device? The answers are not simple and clearly depend on the prosthetic facilities available in the region. More importantly, it will depend on the financial support available. Countries where explosive remnants of war are an important problem include those where lack of development and the presence of social disorder are endemic. Consequently, prosthetic facilities are limited and prostheses cannot readily be provided for children who lose their upper extremities. This is a particular problem in children since they are growing and such prostheses would have to be replaced on almost a yearly basis. For such children, the Krukenberg procedure provides for sensate function that is not associated with the cost of a prosthesis or the costs of recurring need for repairs and replacements due to growth.

### Contraindications

Krukenberg’s operation cannot be used when there is a radio-ulnar synostosis or significant elbow abnormality. It also is not indicated when the skin of the forearm has limited sensibility.

### The Operative Procedure:

The operation is done using a tourniquet. The forearm incisions are designed in such a way as to provide as much skin coverage to the distal stumps as possible. One satisfactory method is illustrated Fig. J. An alternative choice is shown in Fig. K. If there is any skin distal to the wrist it is preserved for possible use in covering the distal pincers. In the young pediatric patient an effort must be made to preserve the distal physes (epiphyseal growth plate) of the radius and ulna so that growth may continue. The forearm bones are separated by cutting the interosseus membrane to its proximal extent. The muscles are separated. It is quite important to try to preserve a musculocutaneous flap on the radius comprising the brachioradialis to its distal extent and the extensor carpi radialis longus. This flap should be left attached to the radius. A similar flap can be created on the ulnar side including the flexor carpi ulnaris and the extensor carpi ulnaris. Sensory nerves should be preserved as much as possible. All of the muscles do not need to be preserved, and in fact several need to be removed to



permit closure of the wounds without undue tension.

When separating the bones of the forearm, we recommend that you obtain as much separation as possible without injuring the capsule of the proximal radio-ulnar joint or of the radio-capitellar joint.

The length of the pincers is determined by the distance between the pronator teres and the distal bone. It is desirable to have at least 6-8 cm, but a shorter distance could be tolerated especially where additional growth is anticipated. In the child who has attained nearly full growth one could shorten the pincer arms to about one-half the length of the forearm. Pincers that are long tend to have weaker grasp, but do allow larger grasp; thus a compromise needs to be made.

In the growing child the skin closure works better if you start distally and leave proximal areas to be grafted if necessary. Skin graft can be obtained from the proximal forearm, upper arm, or the groin. We release the tourniquet before closing the skin to evaluate the circulation of the flaps. We then leave it down for the remainder of the procedure.

**At the completion of the surgery:** The pincer arms are dressed so that they are separated at the tips by the distance that could be achieved during the procedure without significant tension. The extremity should be elevated for 2-3 days.

### Post-operative care

Active exercise can be started at 2-3 weeks. Try to focus on grasp and release as opposed to pronation and supination.

### Role of Occupational Therapy

#### Pre-op Assessment

Even though children with transcarpal or transradial limb deficiencies can do all or most age appropriate daily living activities without prosthetic or surgical intervention; the Krukenberg surgery does provide an alternative way to perform bimanual tasks. The Krukenberg digits have the potential for excellent functional grasp with intact sensory feedback but the surgery alters the appearance of the limb.

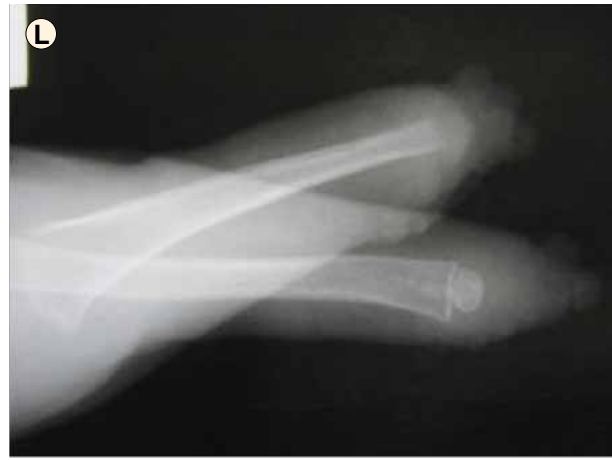Therefore it is important for the patient and family to view a video of functional activities performed by someone with a Krukenberg conversion and then to discuss the surgical ramifications. The child needs to be old enough to understand how the Krukenberg works and how the surgery changes the cosmetic appearance of the limb in order to take part in the decision making process.

***Note:** A video DVD, intended to show parents and patients about the operation so they can understand how the procedure functions and what it looks like, is available through the Global HELP web site.*

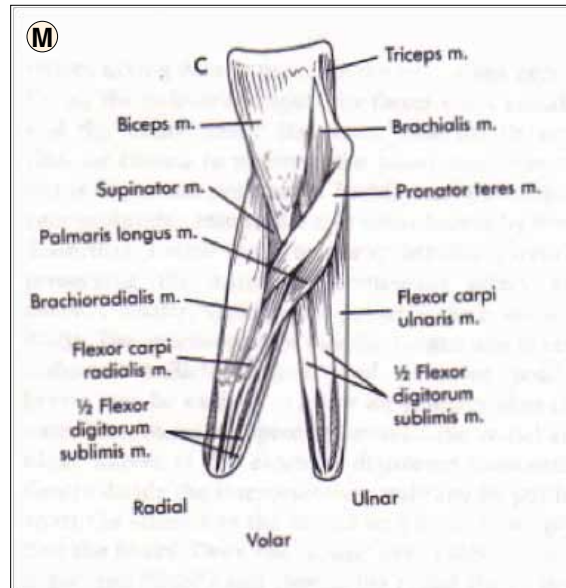
If the patient is a candidate for surgery a functional assessment is done. The child demonstrates how he uses his upper extremities to accomplish selected play and daily living tasks. A record is kept by videotaping the evaluation.

#### Post-operative Therapy

Two to three weeks after surgery, active grasp and release activities begin. The patient must learn to open and close



An x-ray image after a Krukenberg operation in this child shows that the Secondary Centers of Ossification of the distal Radius and Ulnar have been preserved for future growth



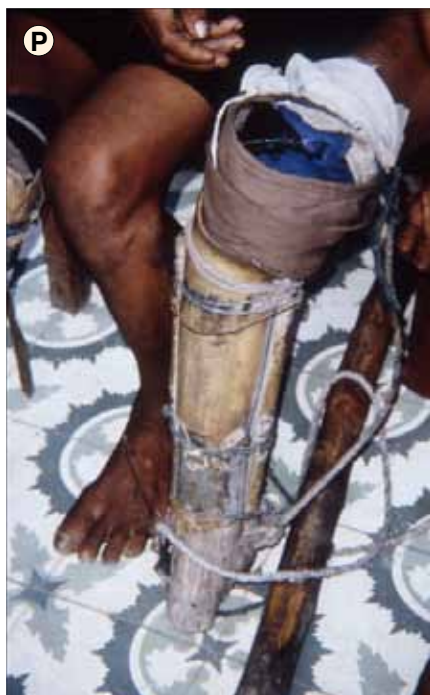Muscles to preserve.



*This child who had her Krukenberg operation eight weeks earlier is receiving instruction from an Occupational Therapist to maximize the her use of the Krukenberg procedure.*



*This child washes the dishes in soapy water which otherwise would harm a prosthesis.*



*This below-knee prosthesis was home-made by a farmer in Vietnam. While such a prosthesis will allow a man in a country with limited prosthetic facilities to do his work, there is no similar home-made arm prosthesis which will allow a child to function better than no prosthesis at all.*

the Krukenberg digits with an abduction / adduction pattern rather than a pronation / supination (scissor type) motion. The therapist assists the patient with the appropriate motion by holding the radial digit firmly in some abduction and maintains the elbow in extension. The patient is asked to flex both elbows against slight resistance to close the digits. The therapist holds the ulnar digit firmly with the elbow flexed.

The patient is asked to extend the elbow against some resistance in order to open the digits.

To reinforce the correct motion the parents or care givers are shown how to assist the child with this exercise. Because the digits are very tender during this initial treatment period, the patient may resist moving them. Both the opening of the digits and pinch force are minimal at this time.

Next the patient practices grasp and release of small objects such as pegs or blocks ( $\frac{1}{2}$  to  $\frac{3}{4}$  of an inch in diameter). Initially the therapist places the items between the digits and later asks the child to grasp them from a table surface. To desensitize the tender Krukenberg digits and increase the patient's comfort, activity can be done in a basin of warm water, or in a mild whirlpool. The water facilitates closure of the digits to squeeze soft toys or small pieces of wet sponge.

As the patient heals he can increase pinch and grip force between the digits by squeezing and pulling apart play dough and other resistive materials. In time the patient should be able to grasp large objects as well as thin items (like paper) in a secure manner and be able to resist the pull to dislodge them. For most individuals, the grip force is stronger between the more proximal part of the Krukenberg digits. Bimanual activities such as toys, games, crafts and daily living tasks are an integral part of therapy. Purposeful activities are often the most effective method to encourage use of the Krukenberg digits in a natural and spontaneous manner.

## Summary

The purpose of the Krukenberg procedure in children is to provide sensate pinch to children who are neurologically intact and have a functional forearm and upper extremity, but are missing one or both hands. The operation is accomplished by splitting the forearm bones and creating two sensate pincers that can be used to grasp objects.

The advantages of the procedure are that it creates sensate pinch that allows skillful manipulation without the need to visually monitor it and it creates a durable extremity. The elements of a child's world such as water, sand and dirt will not affect its function. There is no need to constantly replace an outgrown prosthetic socket, nor is there need for continuing prosthetic repairs. The disadvantages are related to surgeons, parents, and peers who may have difficulty adjusting to the appearance of the arm.

In our opinion, this procedure is an appropriate choice of treatment for a child with a unilateral or bilateral amputation at the level of the wrist or the proximal metacarpals whether or not the child is able to see normally. We offer the operation to children who are developmentally over four years old because we believe that post-operative training would be more difficult at an earlier age. Then each family can decide for themselves if they wish to proceed.



## References:

- 1) Krukenberg H. Über Plastische Umwertung von Armamputationsstrumpfer, Ferdinand and Enke, Stuttgart
- 2) Colp R, and Ransohoff N. Ann Surg 97:277 1933
- 3) Albert Swanson and Genevieve DeGroot Swanson in 1964
- 4) Swanson, AB, Swanson, GD. The Krukenberg procedure in the juvenile amputee. Clin Orthop 1980; 148:55-61.
- 5) Lund D, & Fleck B. “No Hands, No feet, No problem” Bookman Publishing and Marketing, 2005
- 6) Burkhalter J: in Rehabilitation of the Hand Surgery and Therapy, Mosby-Year Book, Inc., 1995, Vol II, Editor: Hunter J, Macin E, and Callahan A.; Chapter 60, p 1055
- 7) Harrison S H, and Mayou B. Brit Jour. Plastic Surg, 1977 171-173
- 8) Schwartz A K, Watts HG & Patton JG. “Acceptability of the Krukenberg Operation as Compared to an Upper Extremity Prosthesis to American People in the Non-medical Community” J Ped Ortho B 2009 in press
- 9) Watts HG “Consequences for Children of Explosive Remnants of War” J. Ped Rehabilitation, 209 (in press)
- 10) UNICEF Report, 28 November 2007
- 11) UK Mine Information and Training Centre (MITC)  
<http://www2.army.mod.uk/royalengineers/org/mitc/index.html>
- 12) PBS Program #71 (December 2006) <http://www.publichealthradio.org/index2006.html>
- 113 Kalmanowskij S. Über die Bildung des Krukenbergarmes, Z, Org. Chir 1939 92: 183

Global HELP Organization's rapidly accumulating publications are freely available on our web-site or printed at minimal cost. Please visit our web-site at [www.global-help.org](http://www.global-help.org) or at [www.orthobooks.org](http://www.orthobooks.org).

## **Publications**

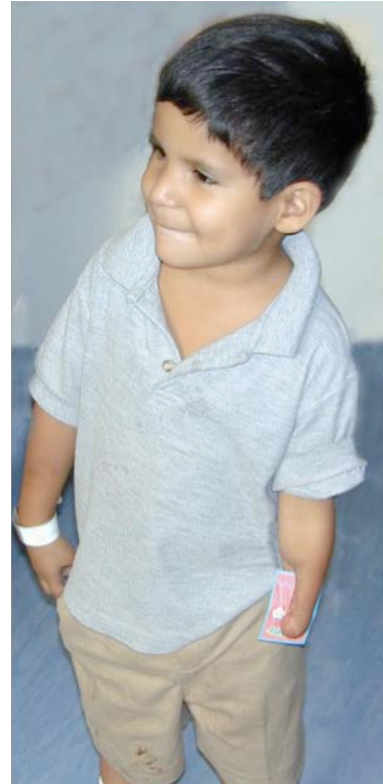All publications from our web-site are free. Publications are available in several forms.

### **PDF for Web site and CD libraries**

All publications are available in PDF format. PDF files can be downloaded from our web-site by clicking on the publication title or image. These files are then copied on your computer and can be printed on personal printers in color or black-and-white. CD libraries include many publications in one convenient compact disc. Some CD libraries are restricted to be used only in developing countries.

### **Printed publications**

Some publications are available for "on demand" printing. Order single or multiple printed copies on our web-site at [www.global-help.org](http://www.global-help.org). These publications are available for only the cost of printing and mailing.



### **Web site addresses:**

[www.global-help.org](http://www.global-help.org)  
[www.orthobooks.org](http://www.orthobooks.org)

### **Send questions, comments or photographs to:**

[questions@global-help.org](mailto:questions@global-help.org)

ISBN 978-1-60189-086-3



**Copyright © 2010 Global HELP**  
**all rights reserved**



**GLOBAL HELP**  
HEALTH EDUCATION USING LOW-COST PUBLICATIONS  
[WWW.GLOBAL-HELP.ORG](http://WWW.GLOBAL-HELP.ORG)